



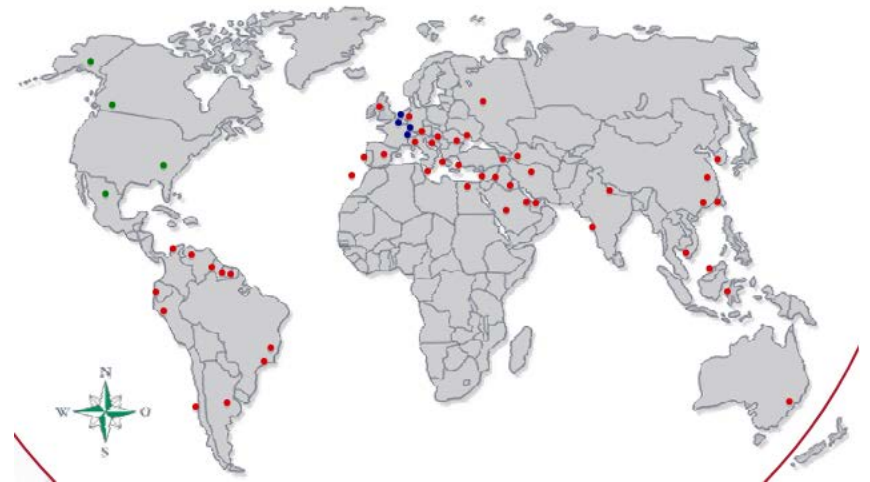Spark Wave® therapy for improved wound healing





MTS Medical UG

- Development & manufacture of Spark Wave™ therapy systems for
 - Orthopedics / Traumatology
 - Wound Care
 - Urology
- Konstanz, Germany
- Global player - internationally registered
- CEO: Nikolaus Hopfenzitz



ORTHOPEDICS



WOUND CARE



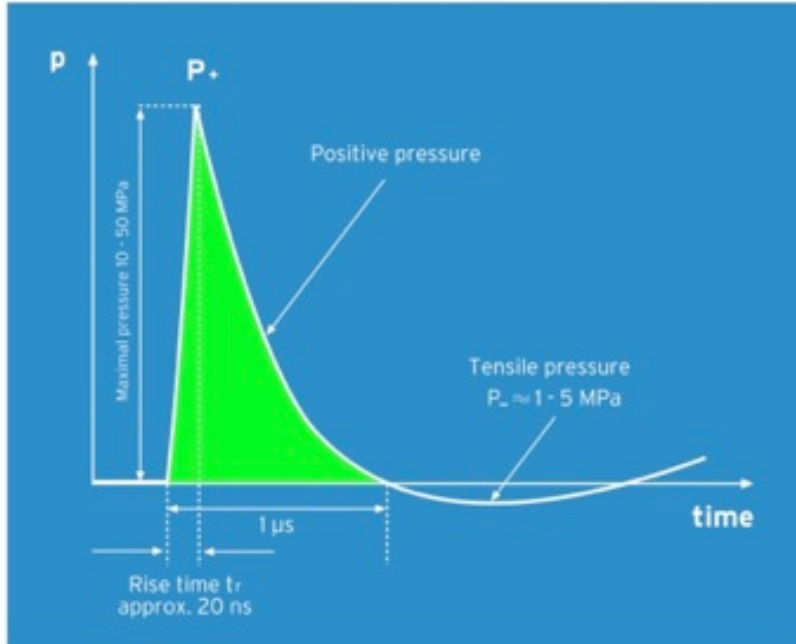
ESWL

ESWL
MADE IN
GERMANY

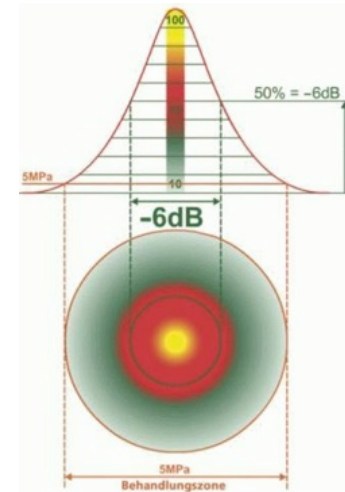


What are Spark Waves®?

- **Spark Waves®**
highly effective shock waves that initiate biological regeneration processes at the cellular level



- **Generating principle**
spark gap in water quench



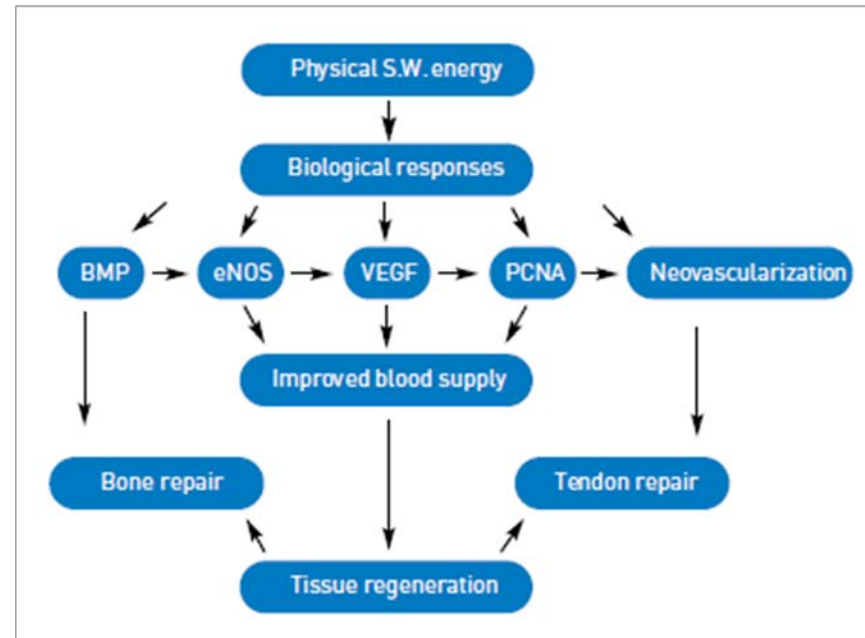
- **Spark Wave™ characteristics:**
 - High peak pressure (up to 100 MPa)
 - Fast pressure rise ($<10 \text{ ns}$)
 - Short lifecycle ($<10 \text{ ms}$)
 - Positive and negative pressure phase

Biological effect of Spark Waves™ in wound healing



Stimulation of healing process on a cellular level by:

- **Bactericidal effect (in vitro)**
- **Reduction of inflammation processes**
- **Bioengineering & Tissue Regeneration**
- **Migration of stem cells**



Source: Wang et al (2006): Biological mechanism of musculoskeletal shockwaves. 9th Congress of the International Society for Musculoskeletal Shockwave Therapy.

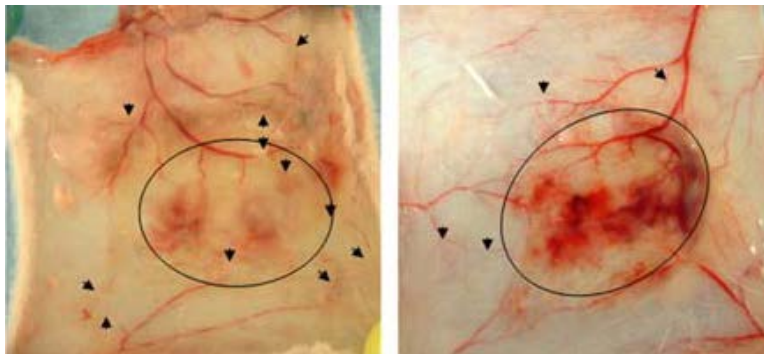


Biological effect of Spark Waves® in wound healing – animal model

Stimulation of healing process at the cellular level by:

- Promotion of body's own production of growth factors (VEGF, eNOS, PCNA etc.)
- Promotion of blood circulation and development of new blood vessels (angiogenesis)

Induced angiogenesis

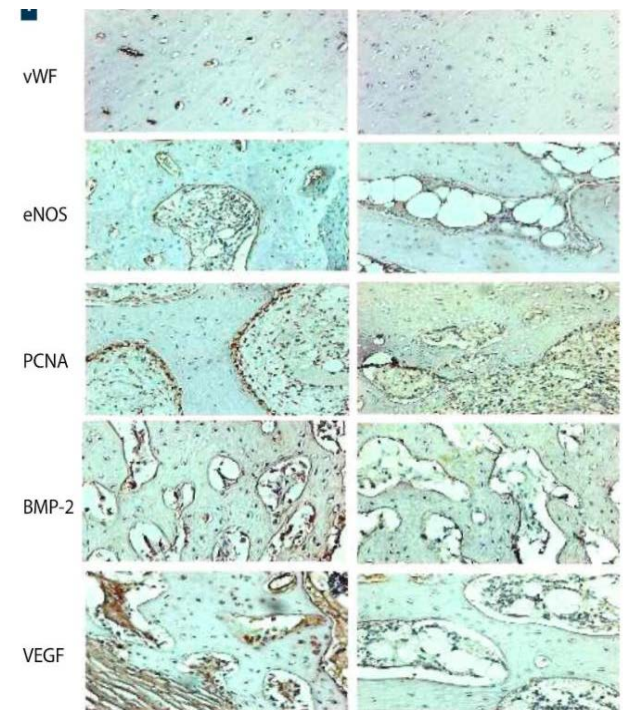


Before ESWT

7 days after ESWT

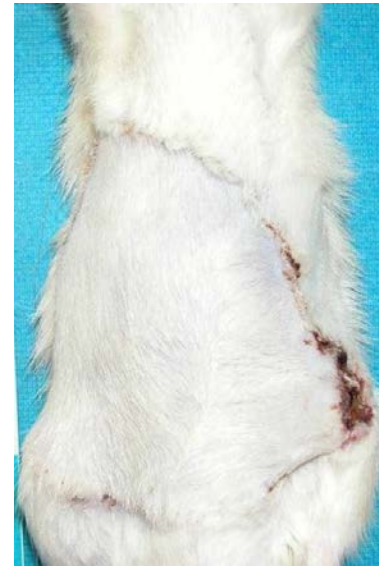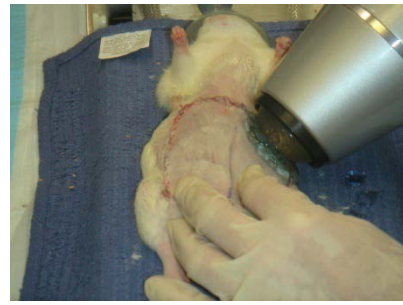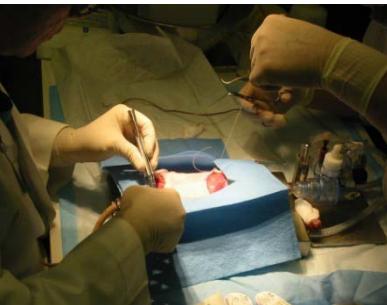
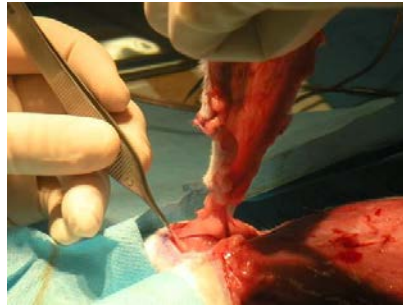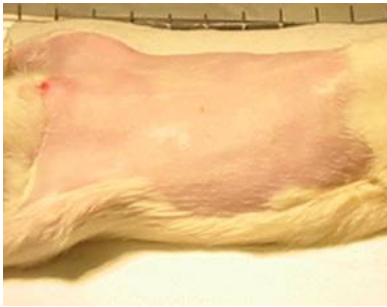
Source: Stojadinovic et al., *Angiogenic response to ESWT in murine skin isografts, Angiogenesis* (2008) 11:369–380

Activation of growth factors

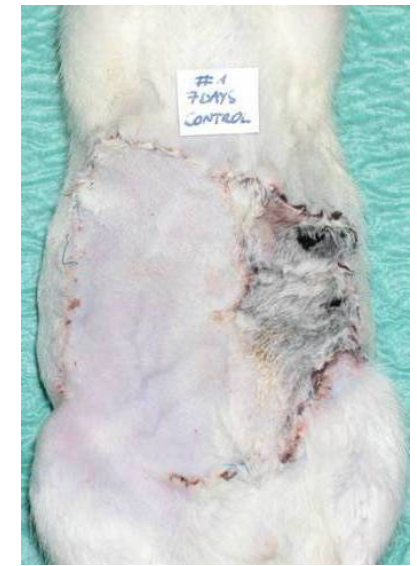

Source: Wang et al. (2006): *Biological Mechanisms of Musculoskeletal Shockwaves. Newsletter (1) of the International Society for Musculoskeletal Shockwaves (ISMT), p. 9.*

Biological effect of Spark Waves® in wound healing – animal model



**ESWT Group, 7 days
post-op**



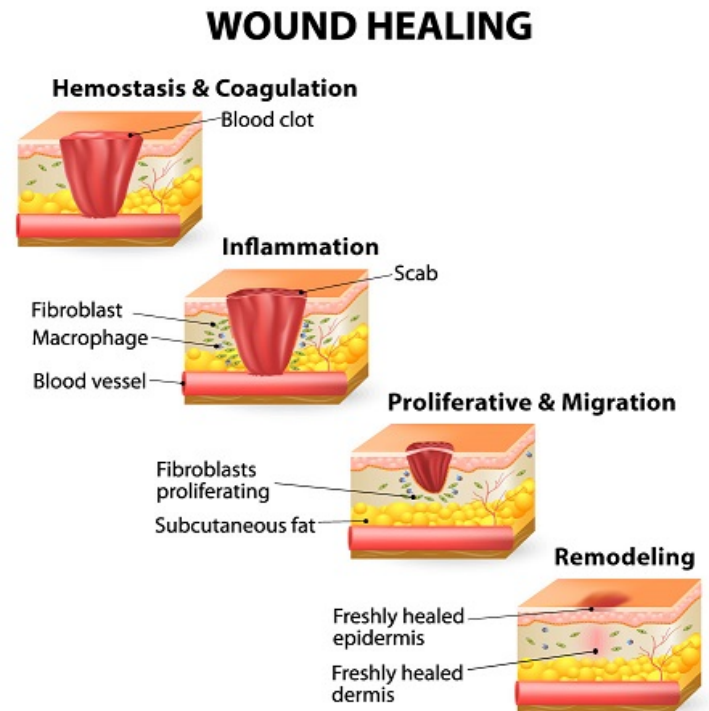
**Control Group, 7 days
post-op**

Source of pictures: Edelmann et al_ A study of the biological factors and wound healing of a skin flap model treated with unfocused extracorporeal shockwave therapy, 2007



dermagold100® - Indications

- **Non-healing, acute and chronic skin lesions**
- **Post-traumatic lesions**
- **Post-operative healing disorders**
- **Venous & arterial ulcers**
- **Decubitus ulcers**
- **Diabetic Foot Syndrome**
- **Burn injuries**
- **Stretch marks, cellulite**
- **Reduction/ smoothing of scar tissue**

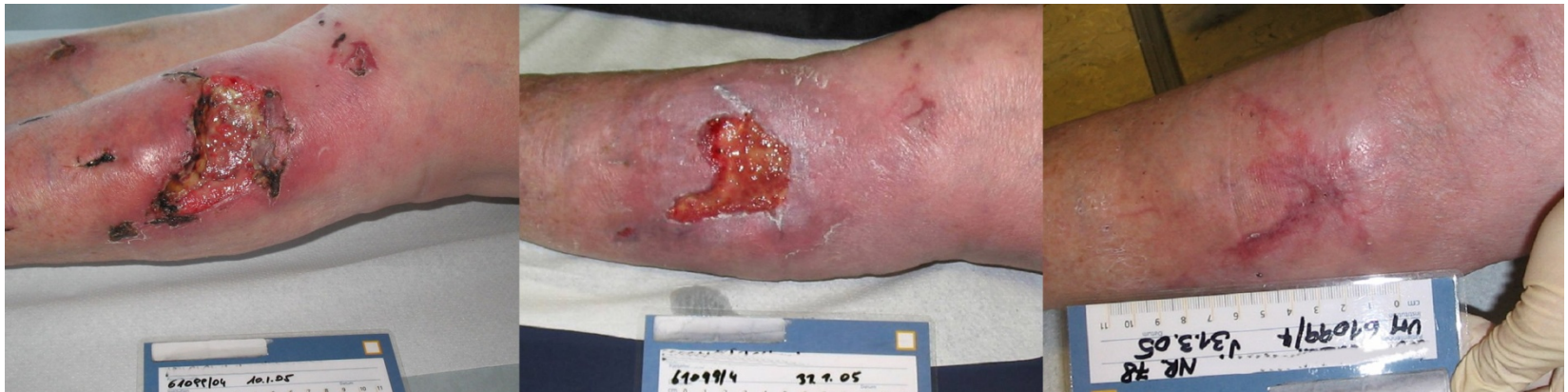

(Figure taken from: <https://dimensionaldermatology.com>)

Spark Wave® therapy for trauma wounds

Infected dog bite

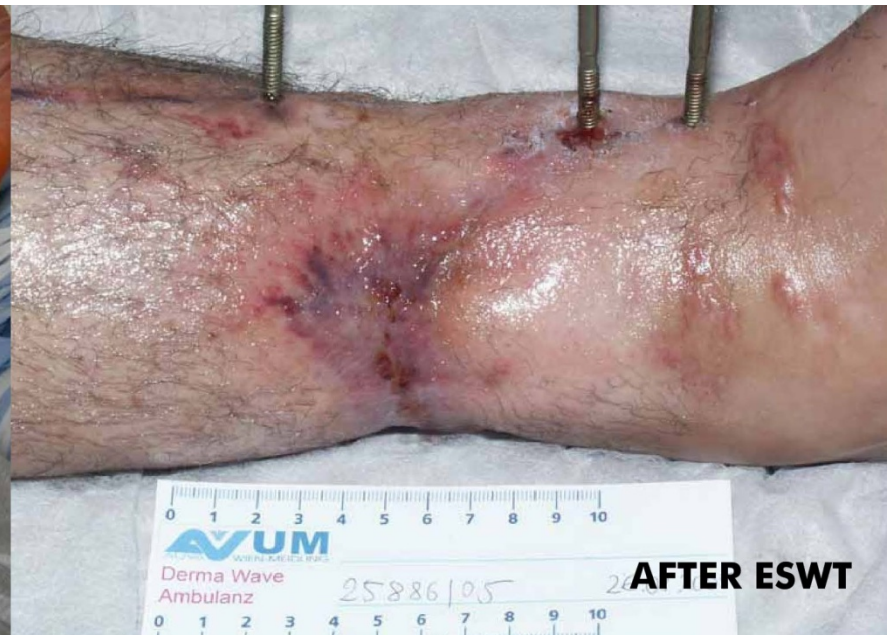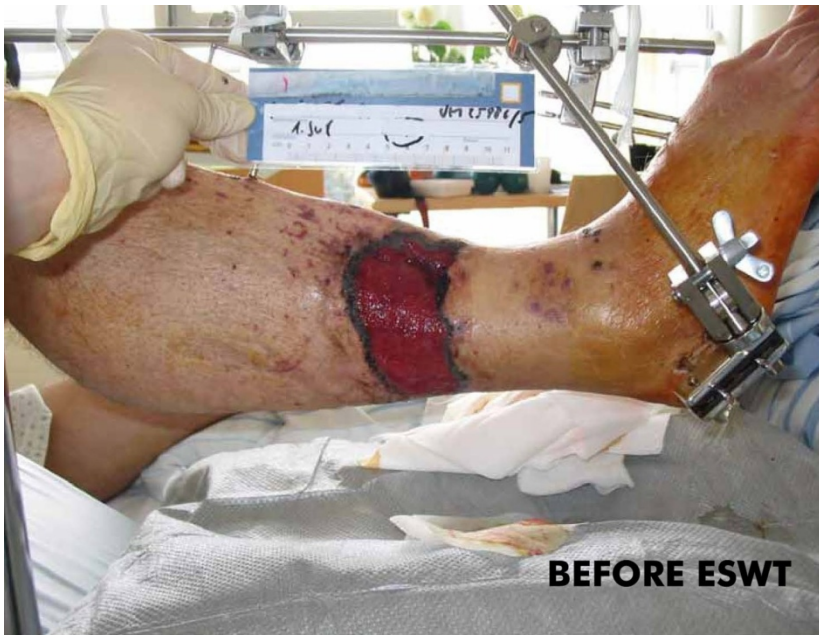Before, after 3 weeks and after 11 weeks / 4 sessions of SWT applied



Spark Wave® therapy for trauma wounds

Non-healing lesion after trauma injury

Before and 8 weeks after SWT / 3 SWT sessions applied

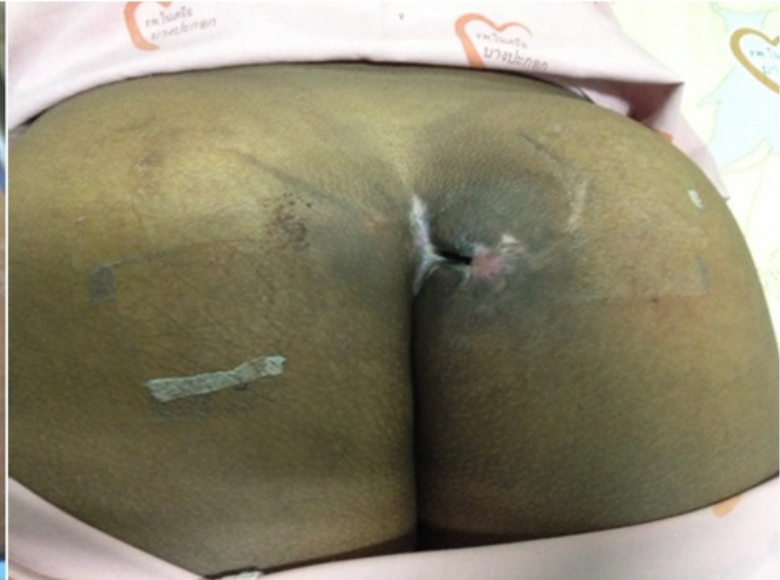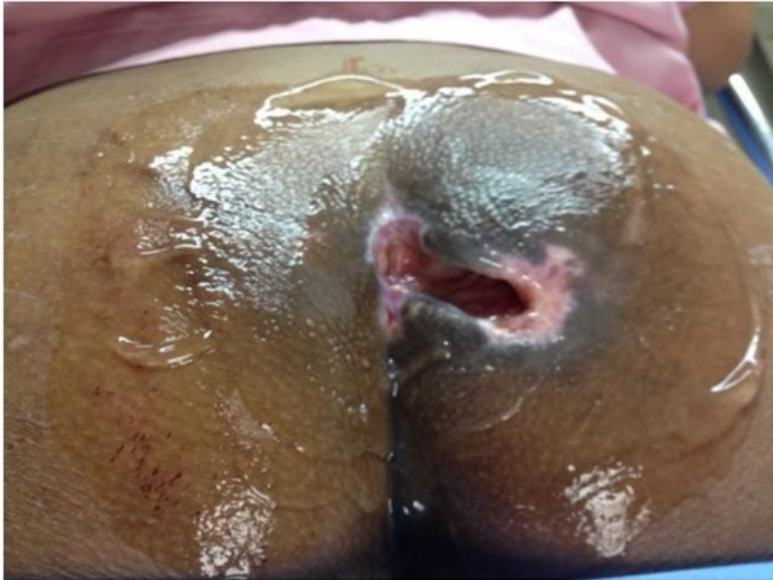


Spark Wave® therapy for burn injuries



Electrical burn, wound size 6x2x6cm, persistent for 3 months

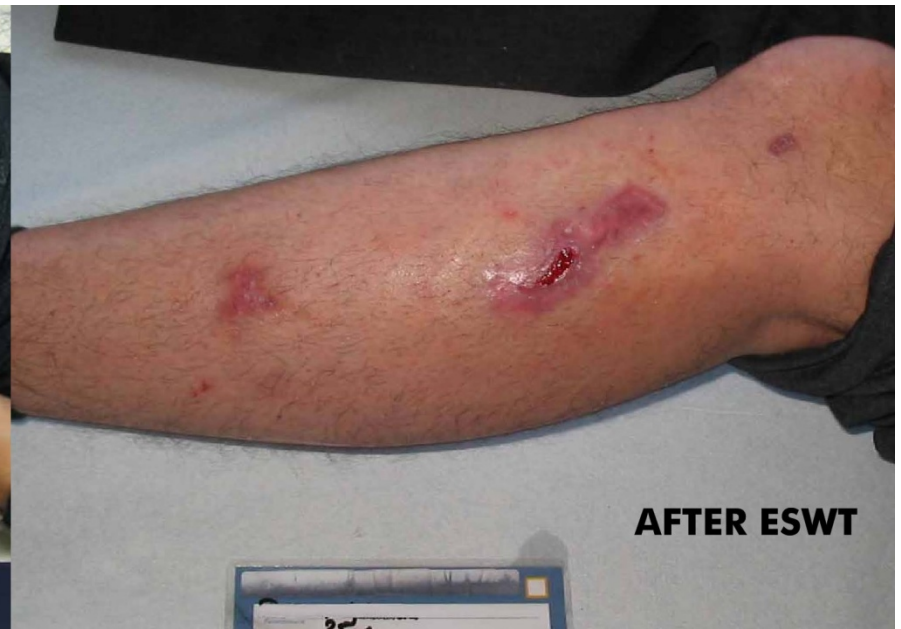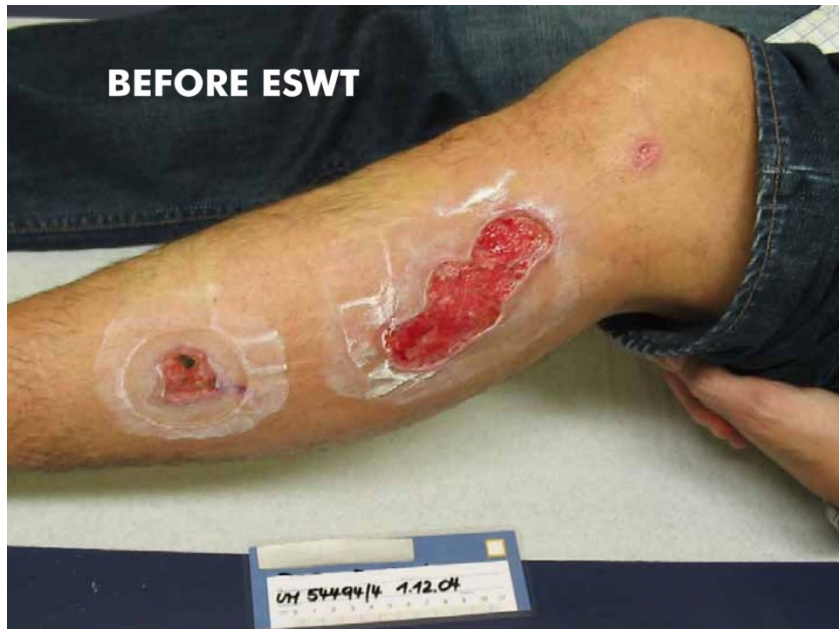Before and after SWT treatment / 4 sessions in total applied over a period of 28 days



Spark Wave® therapy for burn injuries

Burn injury

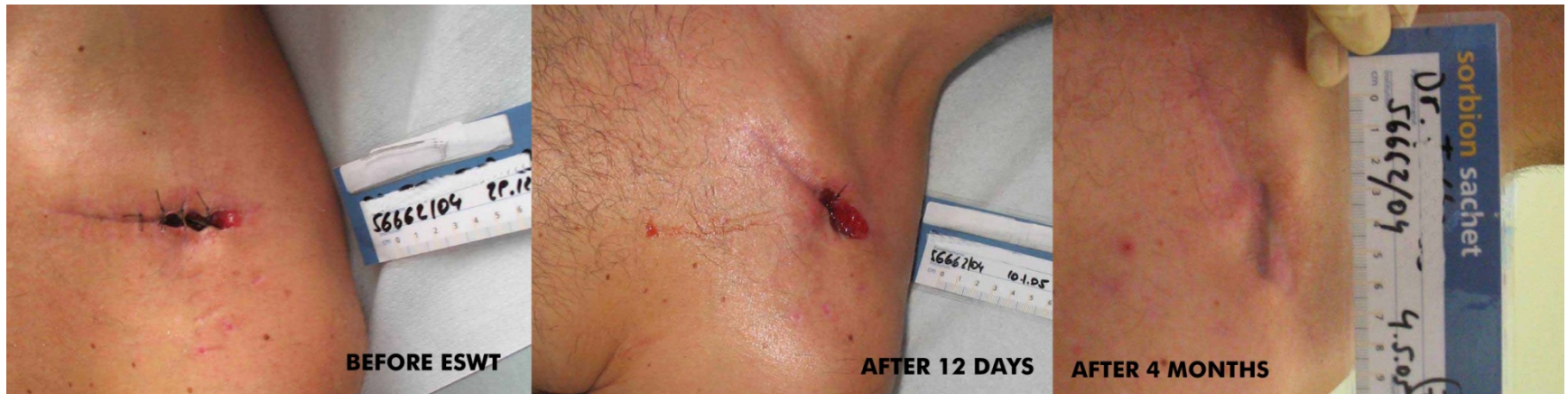Before and after 7 weeks / 4 SWT sessions applied in total



Spark Wave® therapy for trauma wounds

Post operative healing disorder

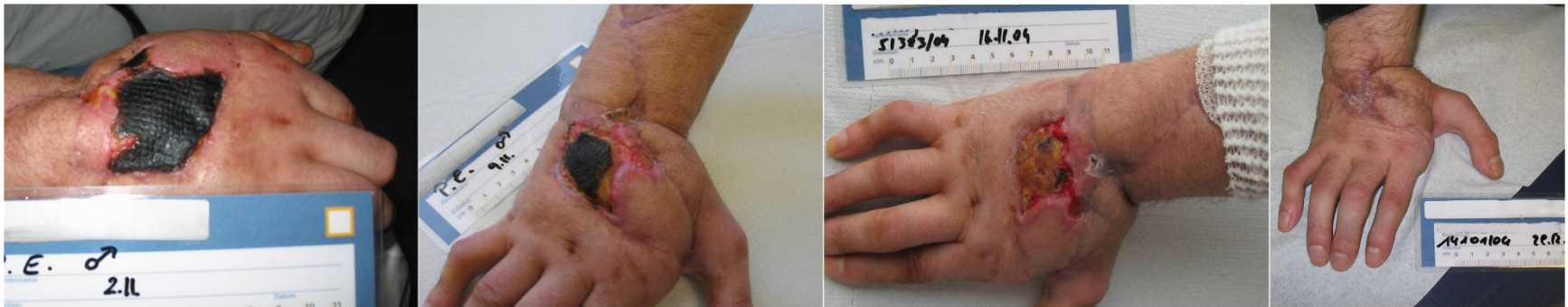Before, after 2 weeks and after 17 weeks / 2 sessions of SWT applied



Spark Wave® therapy for trauma wounds

Trauma injury

Before, after 1 week, after 2 weeks and after 8 weeks / 4 SWT sessions applied

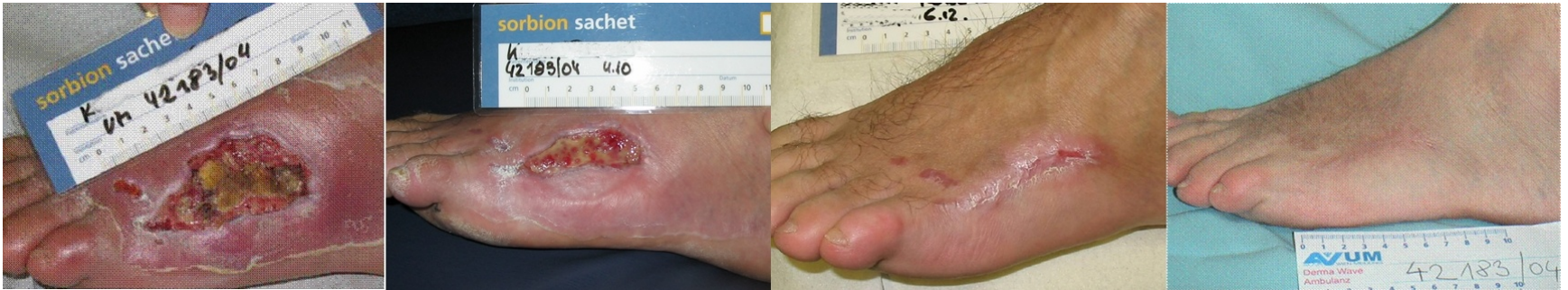

Spark Wave® therapy for trauma wounds

Trauma injury by rotating ship's propeller

47 year old male

Before SWT, after 3 weeks, after 11 weeks and after 26 months / in total 6 SWT applied

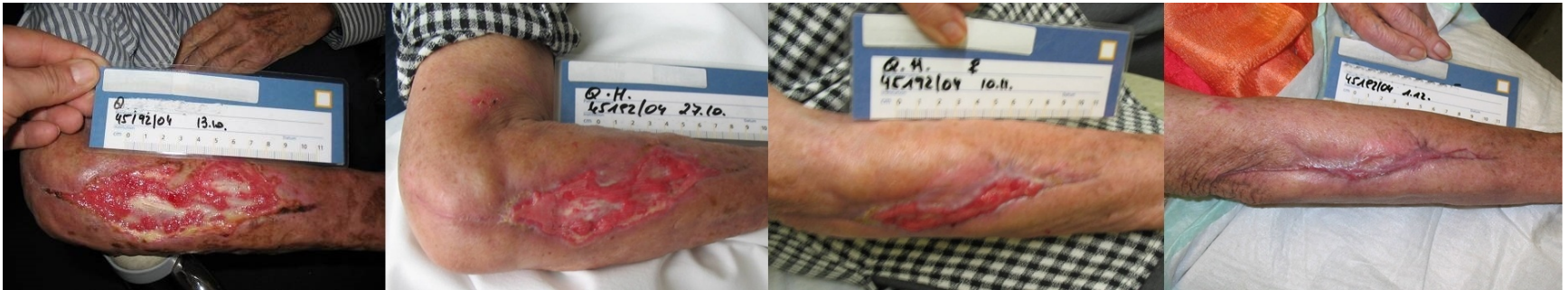

Spark Wave® therapy for trauma wounds

Healing disorder

94 year old female, para-venously applied infusion and 2 septical revisions, infection with penicilin-resistant staphylococcus aureus, chronic COPD, chronic lymphatic leukemia

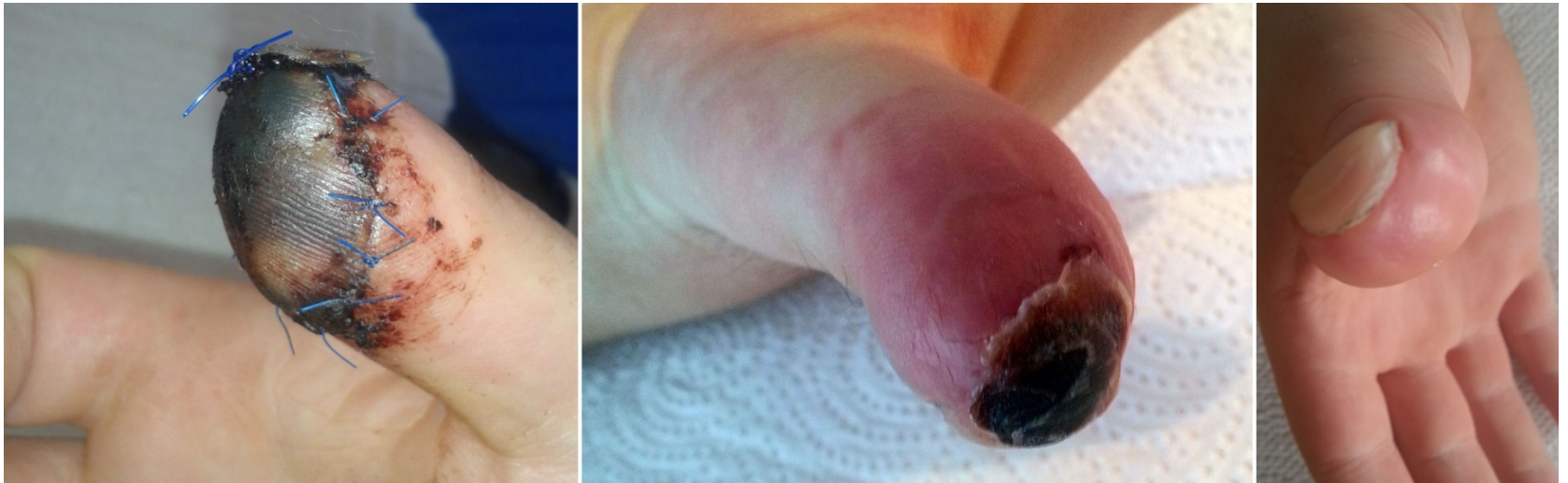Before, after 2 weeks , after 4 weeks and after 7 weeks / in total 4 SWT applied



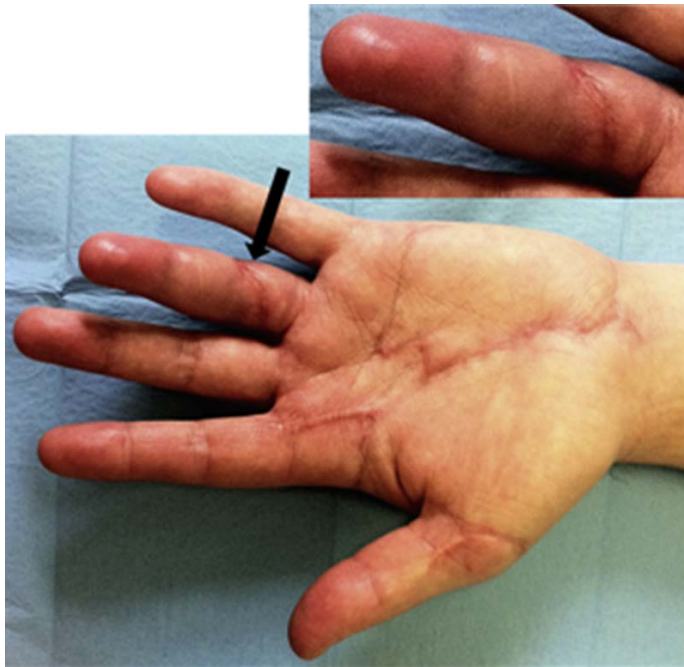Spark Wave® therapy for trauma wounds

Trauma injury / necrotic finger

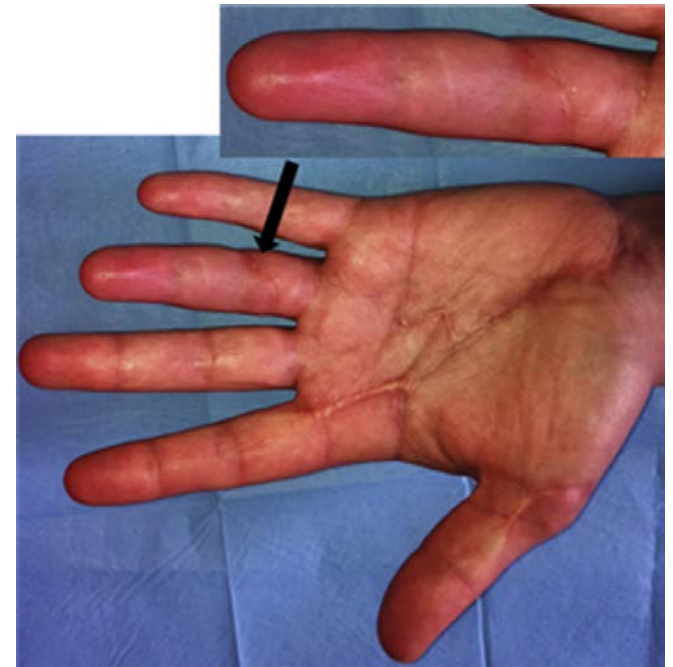Before, after 7 weeks and after 7 months / in total 7 SWT treatments applied



Spark Wave® therapy for trauma wounds – scar treatment

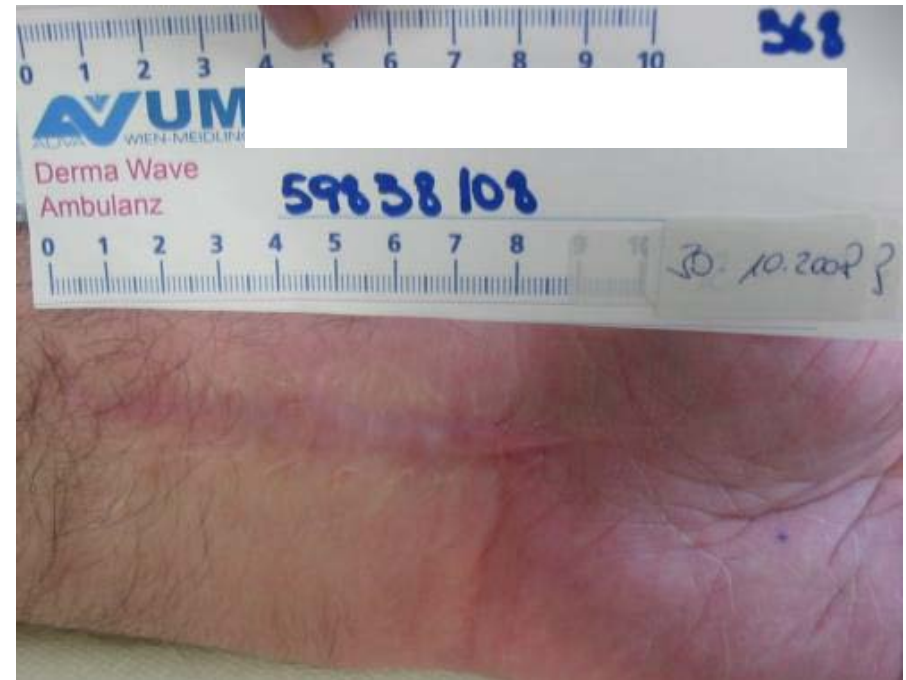
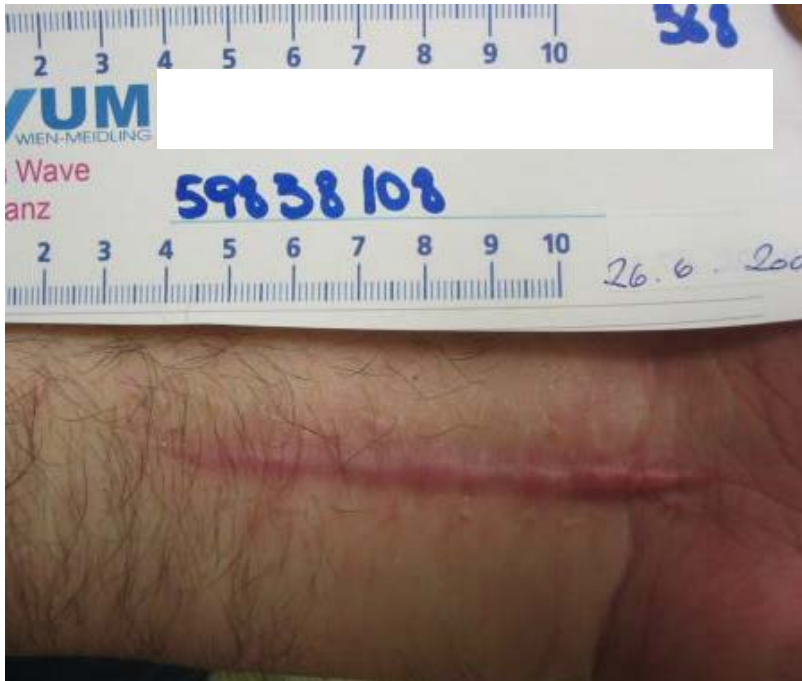
Retracting scar before treatment with ESWT



Retracting scar after 5 weeks of treatment with ESWT

Spark Wave® therapy for trauma wounds – scar treatment



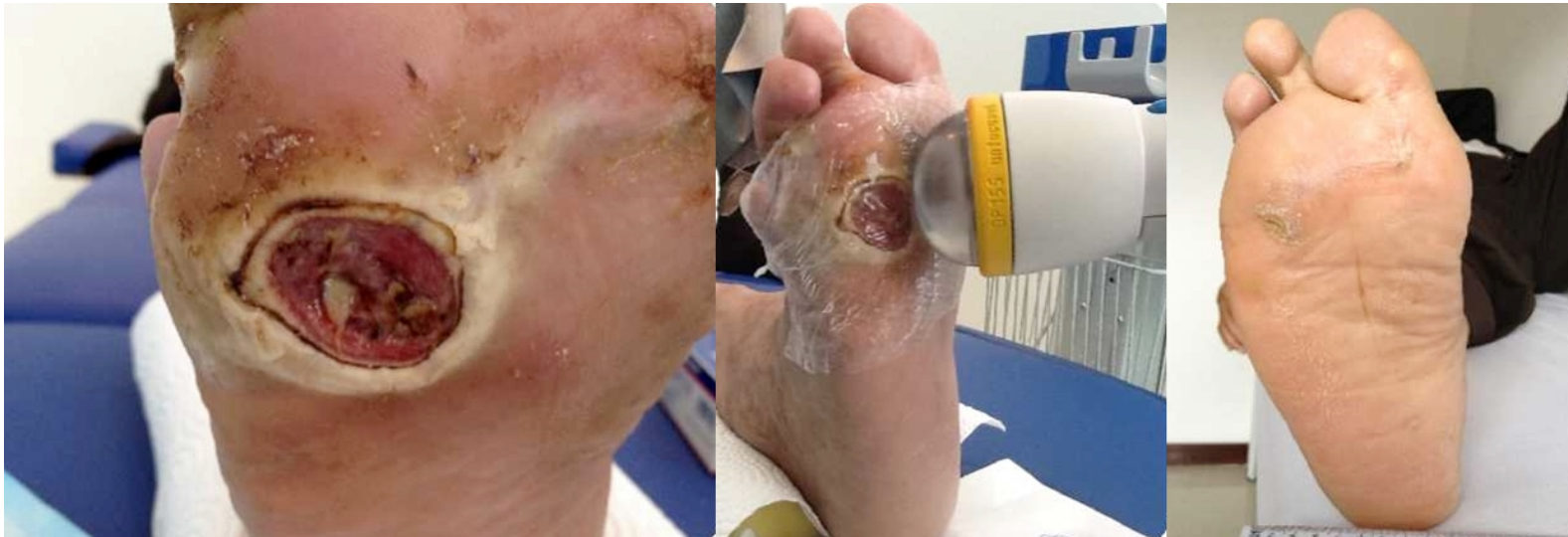53y, male, 11 months after surgery (plating distal radius fracture)
6 treatments (3600 pulses in total / ~ 11 minutes – 4 months)

Spark Wave® therapy for Diabetic Foot Ulcer

Diabetic foot ulcer, duration >4 years

62 year old male, diabetic

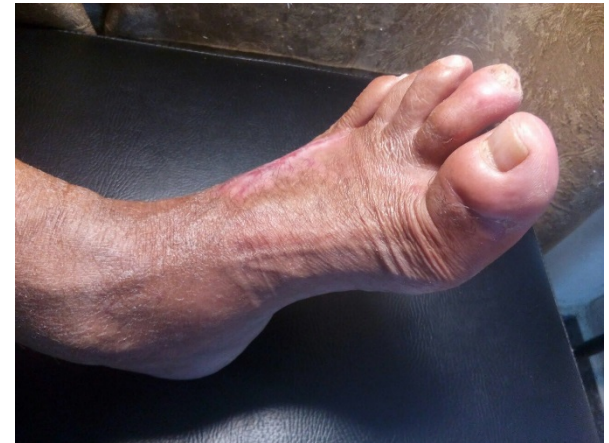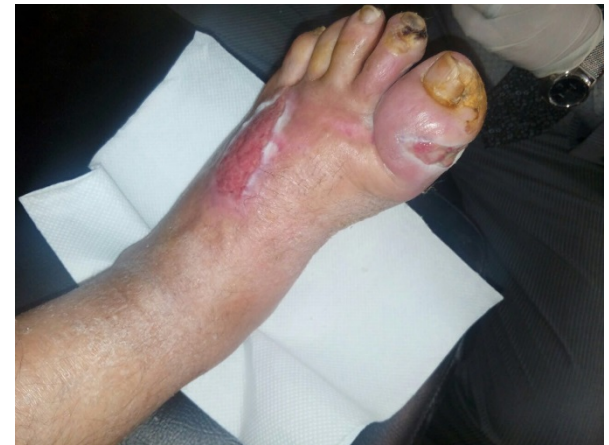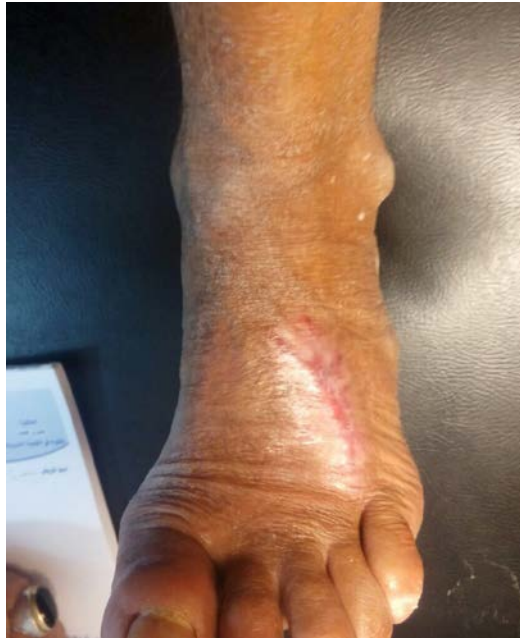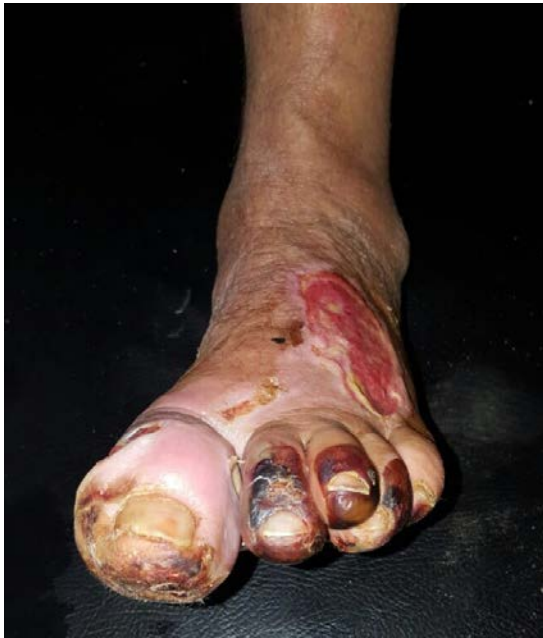Bi-weekly treatment, 4 SWT sessions in total



Spark Wave® therapy for Diabetic Foot Ulcer



Diabetic foot ulcer, before and after treatment with ESWT

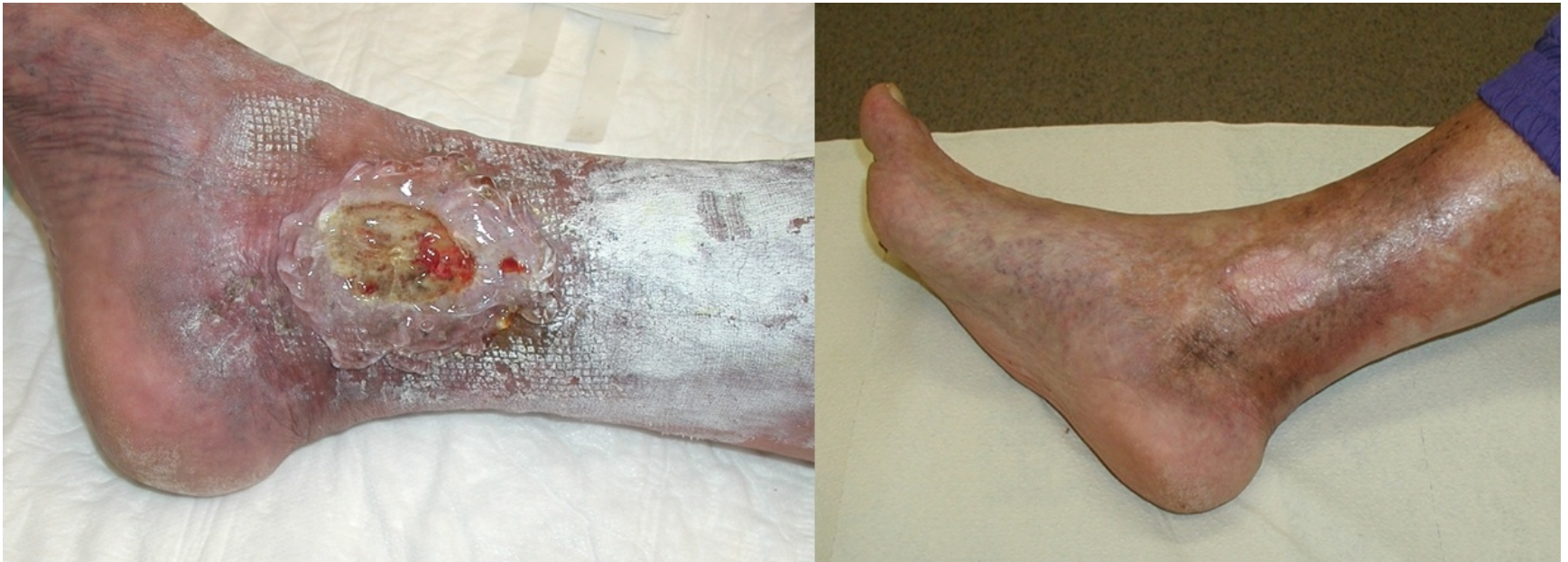

Spark Wave® therapy for Diabetic Foot Ulcer

Chronic diabetic ulcer, duration >1 year

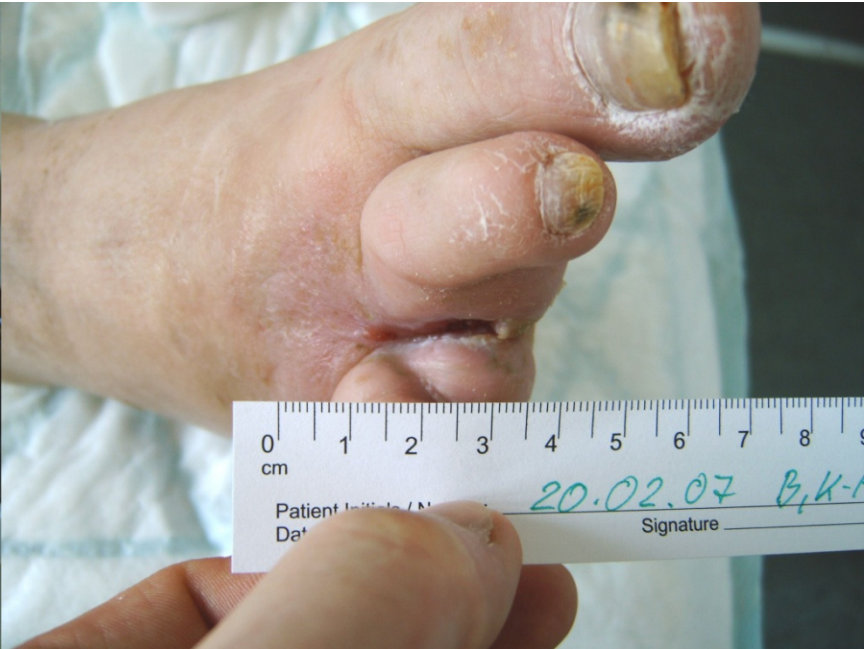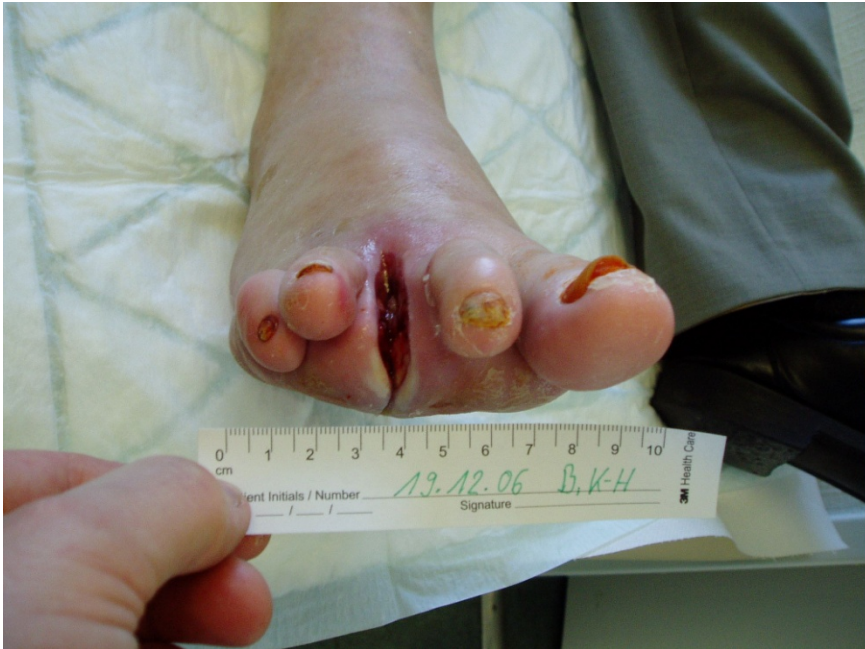57 year old male

Before and 6 weeks after SWT / in total 2 SWT applied



Spark Wave® therapy for Diabetic Foot Ulcer

Diabetic foot ulcer after toe amputation
Bi-weekly treatment for two months

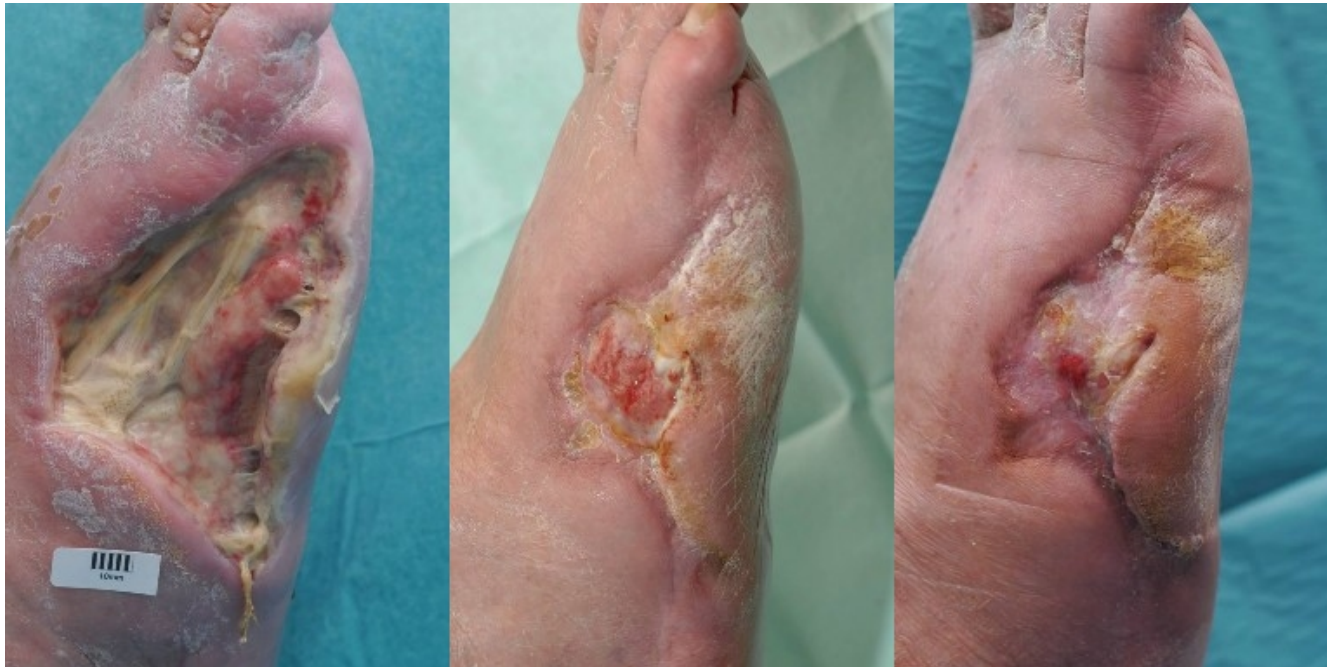

Spark Wave® therapy for Diabetic Foot Ulcer

Diabetic foot ulcer after surgery

47 year old male, diabetic

Before , after 5 months and after 6 months / treatment every 2,5 weeks for 6,5 months

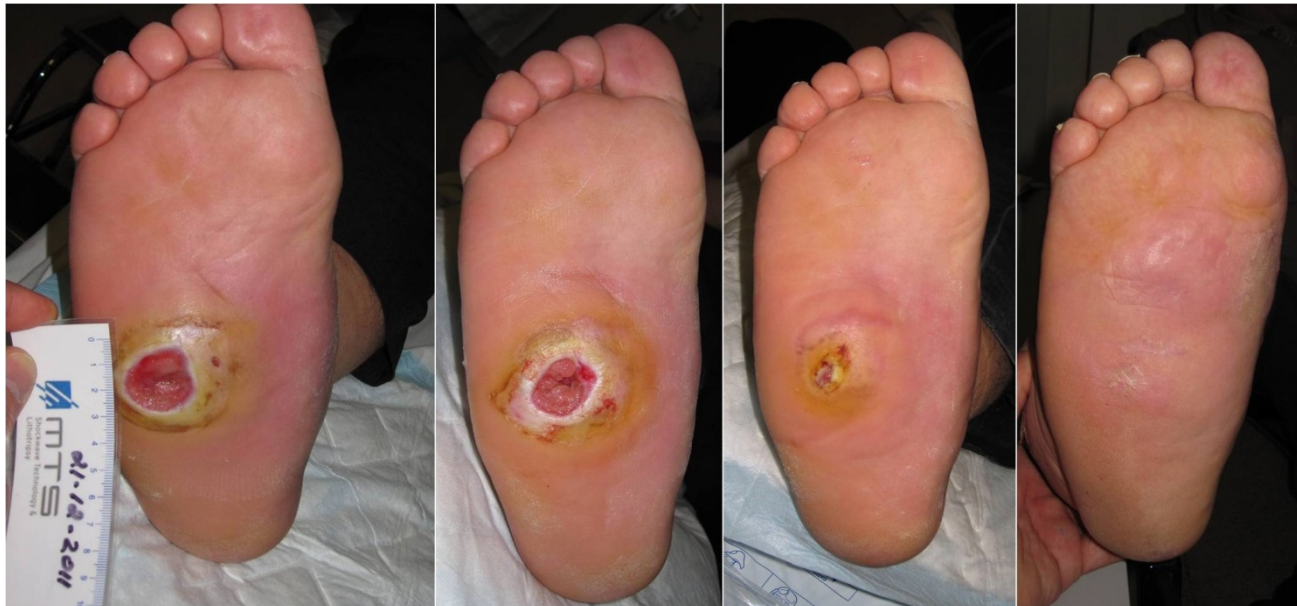



Spark Wave® therapy for Diabetic Foot Ulcer

Diabetic foot ulcer

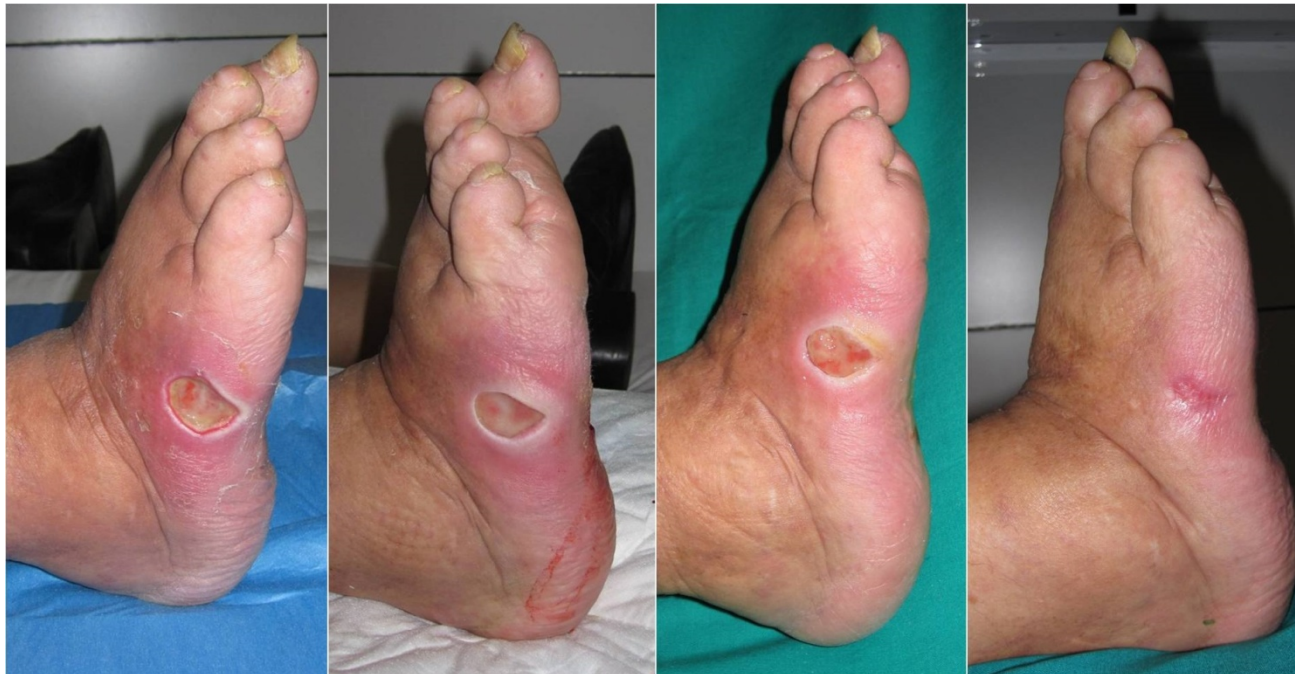68 year old male, diabetic, charcot neuropathy



Spark Wave® therapy for Diabetic Foot Ulcer

Diabetic foot ulcer

71 year old female, diabetic, charcot neuropathy

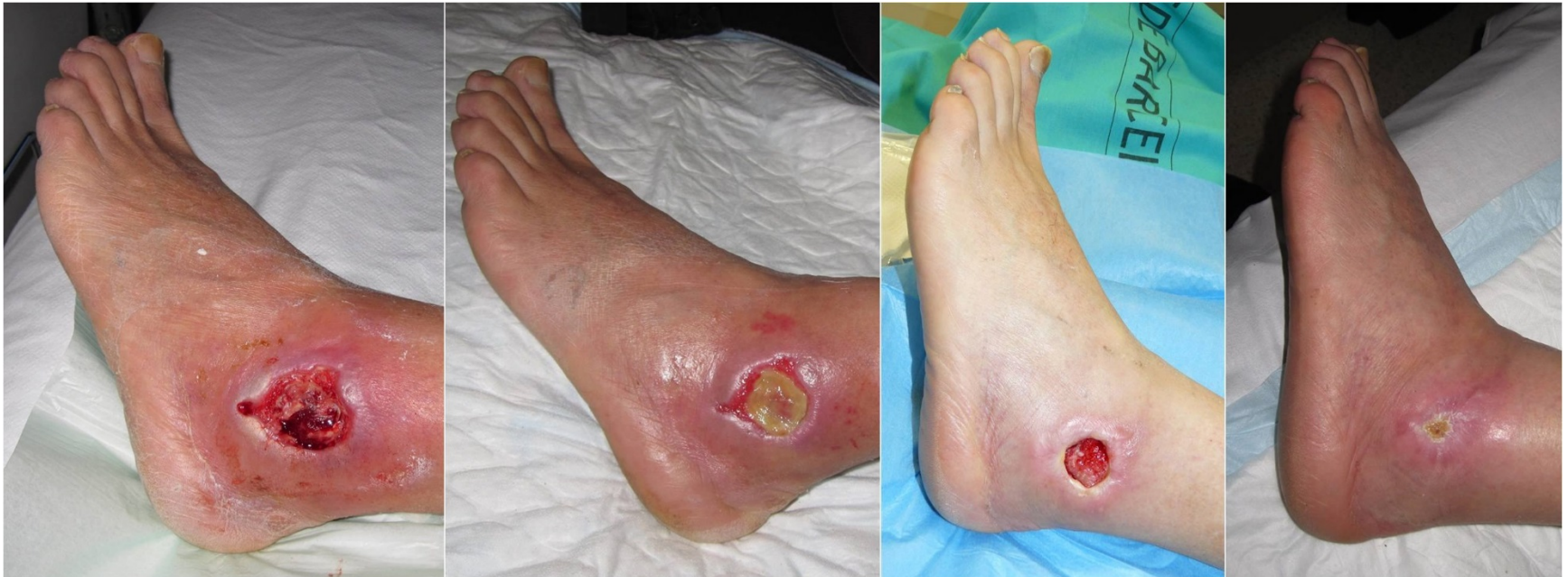



Spark Wave® therapy for Diabetic Foot Ulcer

Diabetic foot ulcer

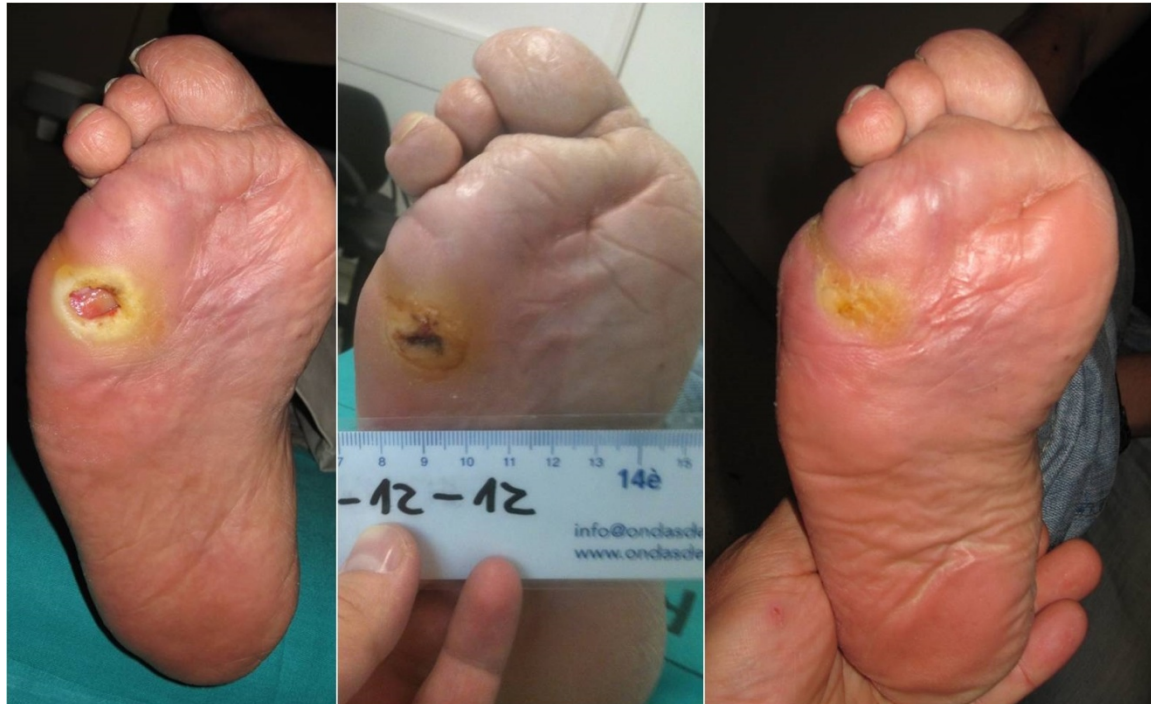67 year old male, diabetic, neuropathy



Spark Wave® therapy for Diabetic Foot Ulcer

Diabetic foot ulcer

68 year old male, diabetic, charcot neuropathy, metatarsal amputation

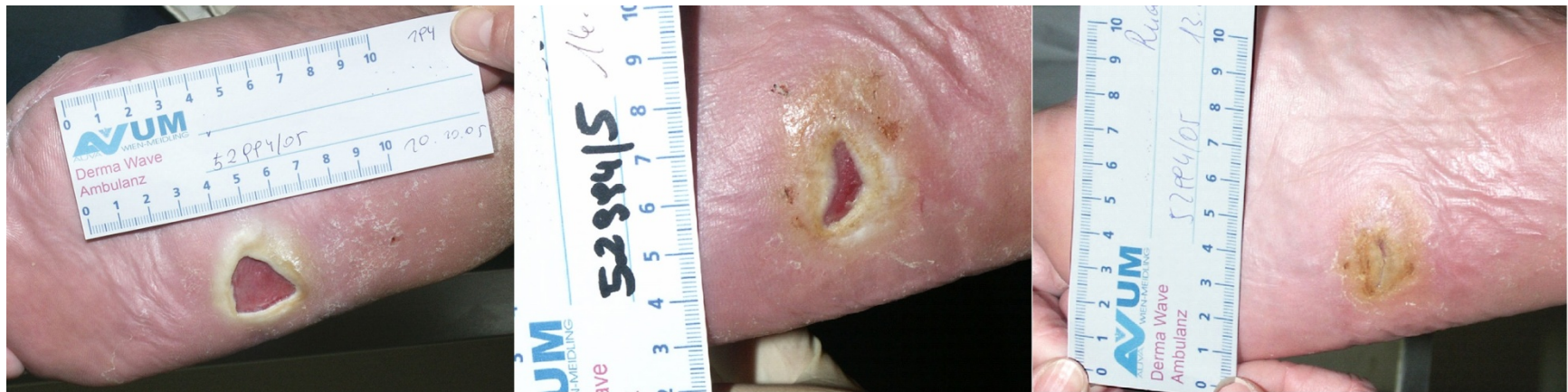



Spark Wave® therapy for Diabetic Foot Ulcer

Diabetic foot ulcer

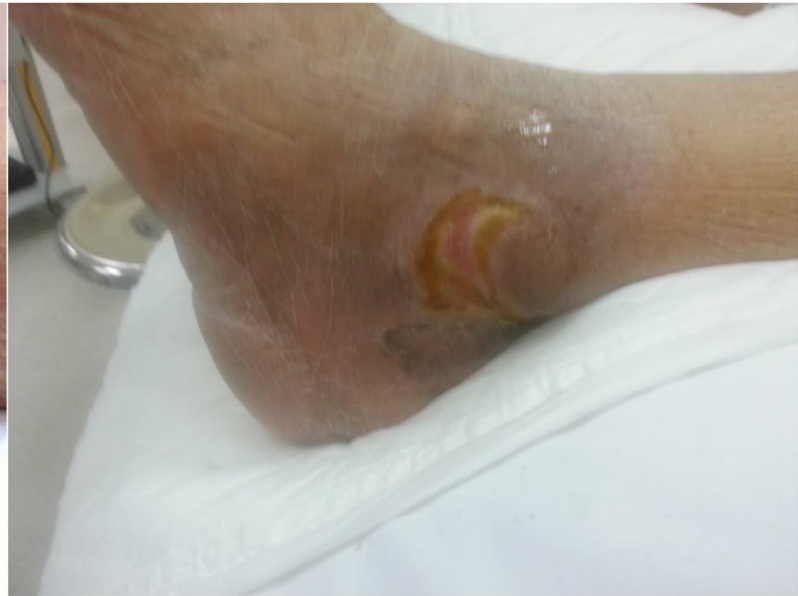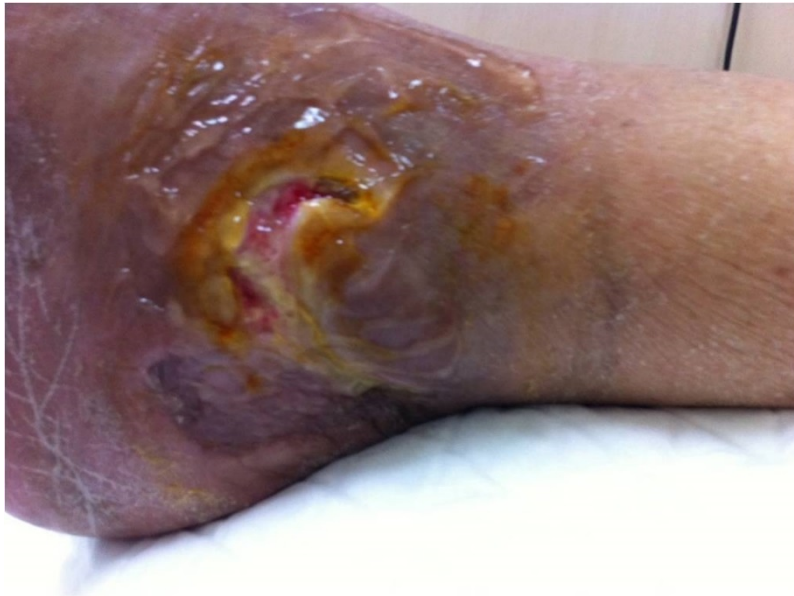Before, after 6 weeks and after 12 weeks / 6 sessions of SWT applied



Spark Wave® therapy for Diabetic Foot Ulcer

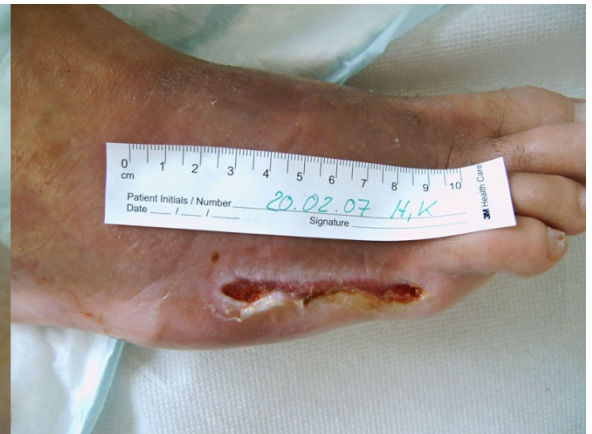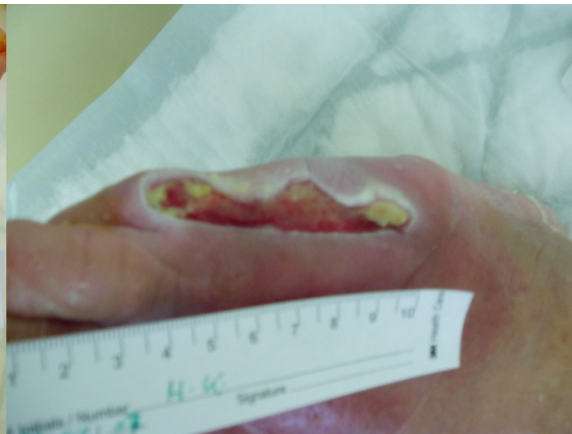
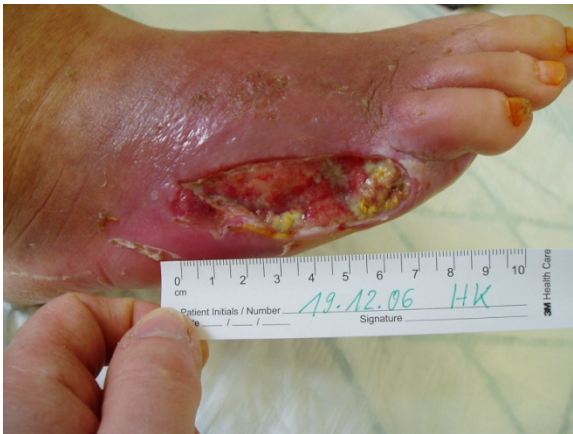Diabetic foot ulcer to the bone, infected

Before and after SWT treatment / in total 6 treatments with 1.500 shocks per session



Spark Wave® therapy for Diabetic Foot Ulcer

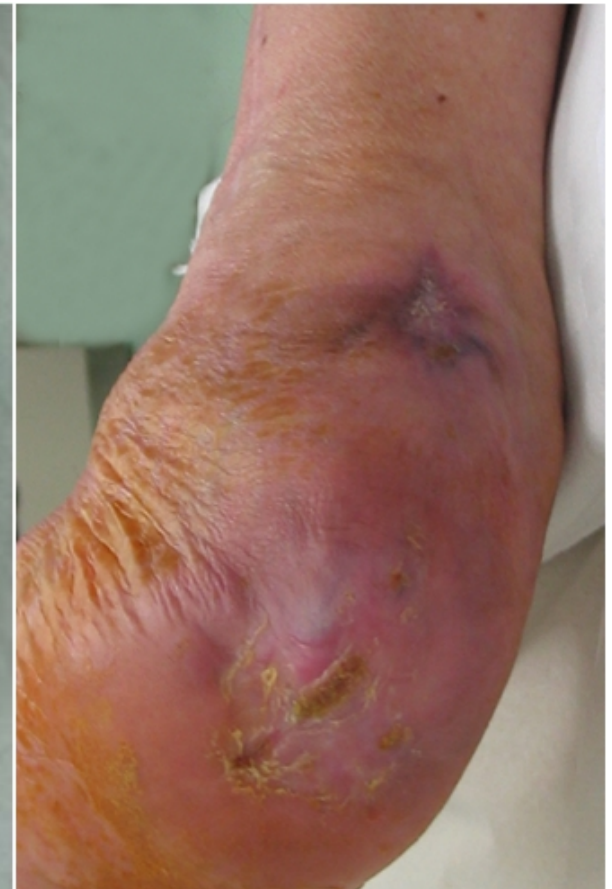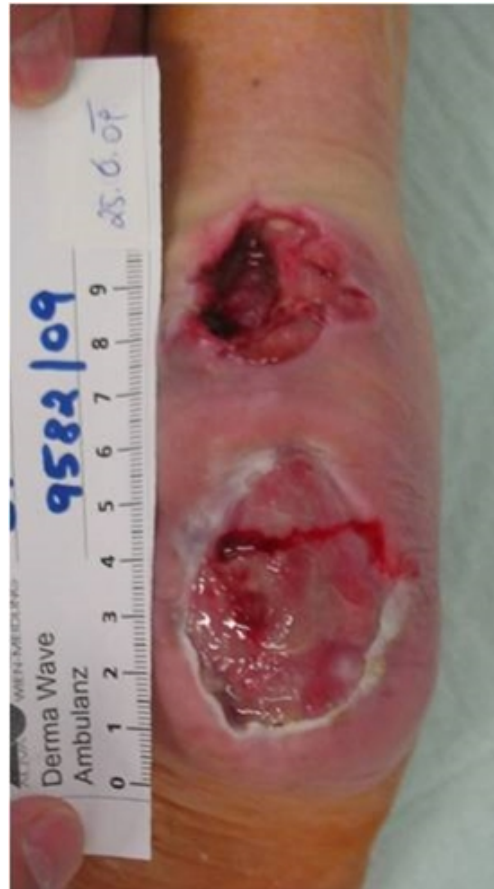Diabetic foot ulcer after amputation
Weekly treatment for two months



Spark Wave® therapy for Diabetic Foot Ulcer

Diabetic foot ulcer after surgical intervention

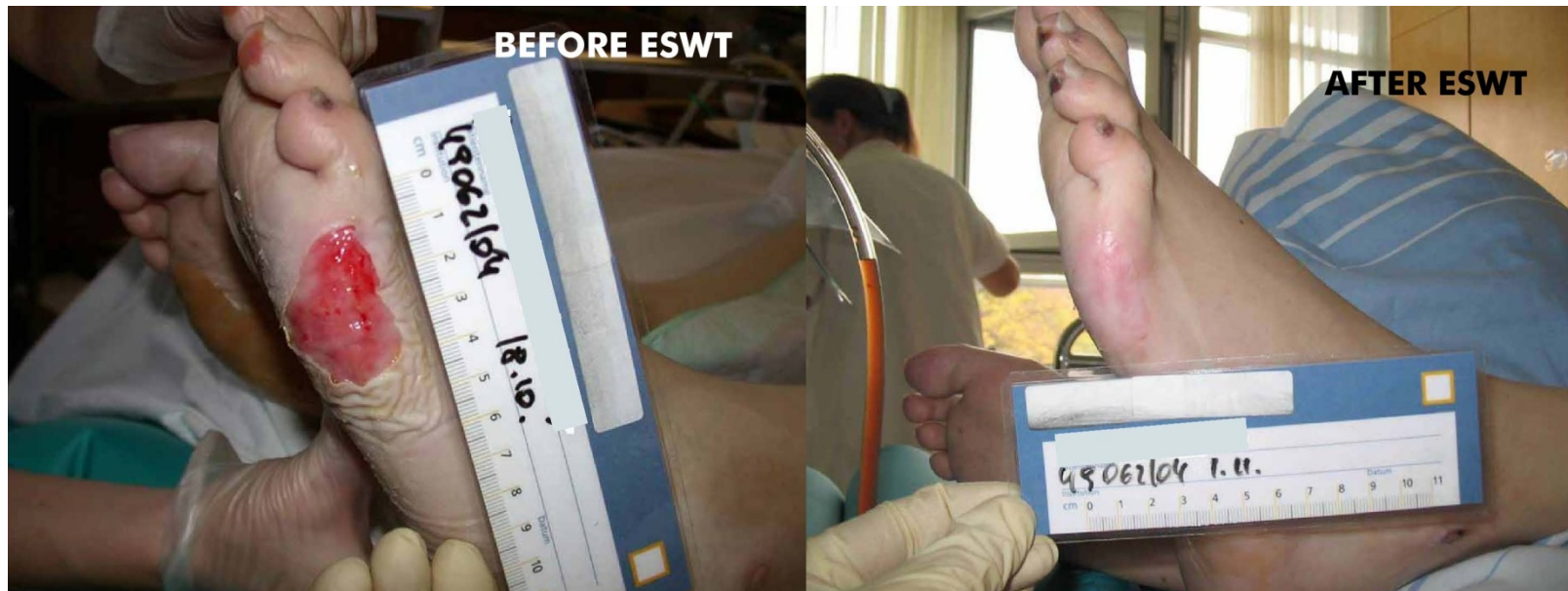
71 years old, female, diabetic
5 SWT treatments in total,
2.500 impulses



Spark Wave® therapy for Pressure Ulcer / Decubitus

Left lateral foot pressure ulcer

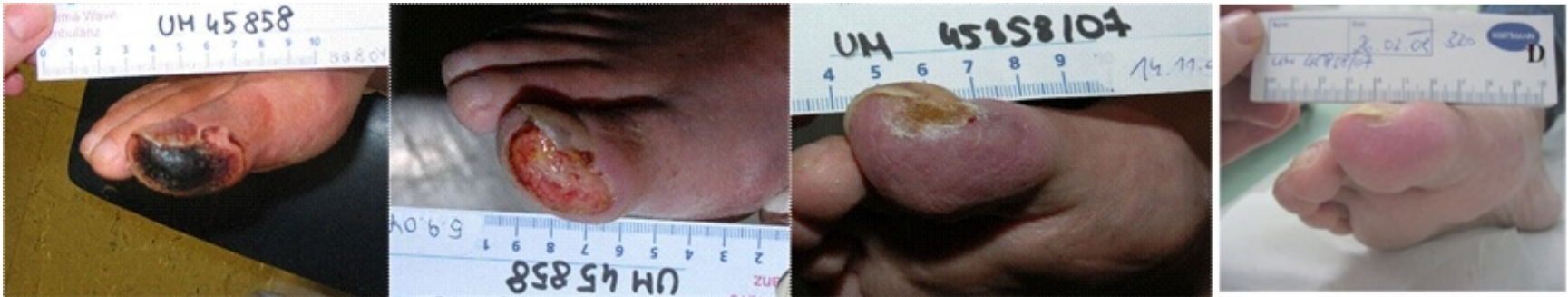50 year old male, before and 2 weeks after single SWT treatment



Spark Wave® therapy for Pressure Ulcer / Decubitus

Decubitus ulcer developed after surgery of an osteosarcoma where patient suffered a lesion of his right sciatic nerve, 39 year old male

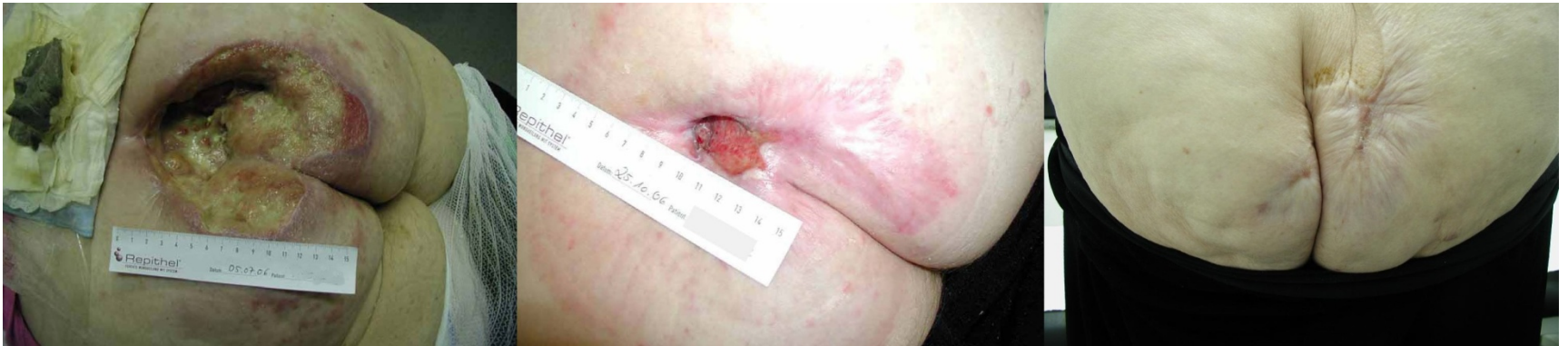Before SWT, after 2 weeks, after 12 weeks and after 18 months / in total 5 SWT applied



Spark Wave® therapy for Pressure Ulcer / Decubitus

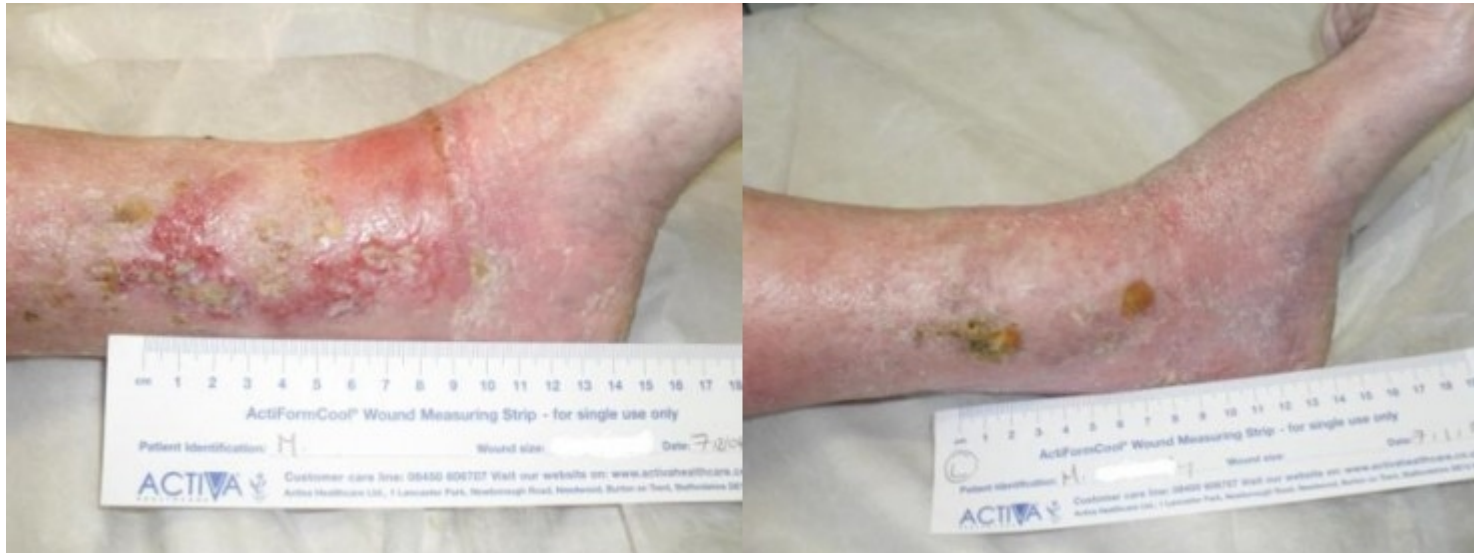Infected decubitus ulcer

Before, after 14 weeks and after 2 years / Weekly SWT sessions for 6 months



Spark Wave® therapy for Venous Ulcer

Venous ulcer on left lower leg, > 5months, 71 year-old female
Before and after 2 treatments / treatment every 2 weeks for 8 weeks in total





MTS publication on wound healing with Spark Wave® Therapy (1/3)

- Hilton. **Study shows shock wave therapy helps heal various skin lesions.** *Dermatology Times*. 2005; Vol.26, No. 9.
- Schaden W. **8. Internationaler Kongress der ISMST – Wirkprinzip Bioengineering.** *Jatros Orthopädie*. 4/2005;12-13.
- Schaden W, Thiele R, Köpl C et al. **Extrakorporale Stosswellentherapie (ESWT) bei Hautläsionen.** *MOT*.2005(5);1-3.
- Schaden W, Thiele R, Kolpl C, et al. **Shock wave therapy for acute and chronic soft tissue wounds: A feasibility study.** *J Surg Res*. 2007; 143:1-12.
- Worcester S. **Shockwave may be next wound healing therapy.** *Skin & Allergy News*. 2007;(7):6
- Stojadinovic A, Elster E, Anam EA, et al. **Angiogenic response to extracorporeal shock wave treatment in murine skin isografts.** *Angiogenesis*. 2008; 11(4):369-380.
- Dumfarth J, Zimpfer D, Vögele-Kadletz, et al. **Prophylactic low-energy shock wave therapy improves wound healing after vein harvesting for coronary artery bypass graft surgery: A prospective, randomized trial.** *Ann Thorac Surg*. 2008; 86:1909-13.
- Kuo, YR, Wang CT, Wang FS et al. **Extracorporeal shock-wave therapy enhanced wound healing via increasing topical blood perfusion and tissue regeneration in a rat model of STZ-induced diabetes.** *Wound Rep Reg*. 2009; 17:522-530..

MTS publication on wound healing with Spark Wave® Therapy (2/3)



- Davis T, Stojadinovic A, Anam K, et al. **Extracorporeal shock wave therapy suppresses the early proinflammatory immune response to a severe cutaneous burn injury.** *Int Wound J.* 2009; 6:11-21.
- Mayer D, Dorfmueller C, Lachat M. **Die extrakorporale Stoßwellentherapie als neue Methode zur Stimulation der Heilung komplexer Wunden: eine Übersicht.** *Zeitschrift für Wundheilung* 2009; 1:232-237
- Mittermayr R, Hartinger J, Dorfmueller C, et al. **La thérapie par ondes de choc extracorporelle (ESWT) dans l'acicatrisation des plaies: technologie, mécanismes, et efficacité clinique.** *Journal des plaies et cicatrisations* 2009; 71:6-16.
- Wang C, Kuo Y, Wu R, et al. **Extracorporeal shockwave treatment for chronic diabetic foot ulcers.** *J Surg Res.* 2009; 152:96-103.
- Larking AM, Duport S, Clinton M, et al. **Randomized control of extracorporeal shock wave therapy versus placebo for chronic decubitus ulceration.** *Clin Rehabil.* 2010; 24(3):222-9.
- Ottomann C, Hartmann B, Tyler j, et al. **Prospective randomized trial of accelerated re-epithelization of skin graft donor sites using extracorporeal shock wave therapy.** *J Am Coll Surg* 2010; 211(3):361-7.
- Mittermayer R, Hartinger J, Antonic V, et al. **Extracorporeal shockwave therapy (ESWT) minimizes ischemic tissue necrosis irrespective of application time and promotes tissue revascularization by stimulating angiogenesis.** *Ann Surg.* 2011; 253(5):1024-32.



MTS publication on wound healing with Spark Wave® Therapy (3/3)

- Antonic V, Mittermayr R, Schaden W, et al. **Evidence supporting extracorporeal shockwave therapy for acute and chronic soft tissue wounds.** *Wounds* 2011; 23(7):204-215.
- Schaden W, Mittermayr R. **Extrakorporale Stoßwellentherapie als innovatives und effizientes Behandlungskonzept bei Wundheilungsstörungen.** *Vasomed.* 2011 (23);222-225.
- Mittermayr R, Antonic V, Hartinger J et al. **Extracorporeal shock wave therapy (ESWT) for wound healing : Technology, mechanisms, and clinical efficacy.** *Wound Repair Regen.* 2012 Jul;20(4):456-65.
- Ottomann C, Stojadinovic A, Lavin P, et al. **Prospective randomized phase II trial of accelerated reepithelialisation of superficial second-degree burn wounds using extracorporeal shock wave therapy.** *Ann Surg.* 2012;255(1):23-9.
- Sansone V, D'Agostino MC, Bonora C, et al. **Early angiogenic response to shock waves in a three-dimensional model of human microvascular endothelial cell culture (HMEC-1).** *Journal of Biological Regulators & Homeostatic Agents* 2012; 26(1):29-37.
- Saggini et. al, **Extracorporeal shock wave therapy: An emerging treatment modality for retracting scars of the hands,** *Ultrasound in Med. & Biol., Vol. 42, No. 1, pp. 185–195, 2016*



Thank you very much for your attention!



MTS Medical UG
Robert-Bosch-Str. 18
78467 Konstanz
Tel.: 07531 36185 – 0
Fax: 07531 36185 - 72
www.mts-medical.com
info@mts-medical.com

